

## ORIGINAL ARTICLE

# Integrative skincare trial of intense pulsed light followed by the phyto-corrective mask, phyto-corrective gel, and resveratrol BE for decreasing post-procedure downtime and improving procedure outcomes in patients with rosacea

Sheila C. Barbarino MD, FACS<sup>1</sup>  | Vivian W. Bucay MD<sup>2</sup> | Joel L. Cohen MD<sup>3,4</sup> | Michael H. Gold MD<sup>5</sup> 

<sup>1</sup>Barbarino Surgical Arts, Austin, Texas, USA

<sup>2</sup>Bucay Center for Dermatology and Aesthetics, San Antonio, Texas, USA

<sup>3</sup>University of California, Irvine, California, USA

<sup>4</sup>AboutSkin Dermatology and DermSurgery, Greenwood Village, Colorado, USA

<sup>5</sup>Gold Skin Care Center, Tennessee Clinical Research Center, Nashville, Tennessee, USA

## Correspondence

Sheila C. Barbarino, Barbarino Surgical Arts, Austin, Texas, USA.

Email: [sheila.barbarino@gmail.com](mailto:sheila.barbarino@gmail.com)

## Abstract

**Background:** Rosacea is a chronic inflammatory skin condition of varying severity that can significantly impact patient quality of life. Intense pulsed light (IPL) is an established treatment for rosacea-associated telangiectasia, inflammation, and erythema. This study assessed whether application of a phyto-corrective mask, gel, and resveratrol antioxidant serum after IPL treatment can improve outcomes and reduce procedure-related adverse effects.

**Methods:** In a prospective, open-label, split-face, 3-month study, 10 subjects with moderate-to-severe facial rosacea underwent IPL treatment on both sides of the face. The following were applied to the right side of the face only: phyto-corrective mask once weekly starting immediately after IPL; phyto-corrective gel twice daily; and resveratrol antioxidant treatment at night. Both sides of the face were treated with sunscreen. Subjects were assessed on Day 1, 1 and 3 months after IPL by three, independent evaluators using the 5-point Global Aesthetic Improvement Scale (GAIS). All subjects rated skin redness, hydration, and overall improvement on Day 1 and completed a patient satisfaction questionnaire at the 1- and 3-month visits.

**Results:** Ten women were enrolled, aged 44–72 years old, with moderate ( $n = 6$ ) to severe ( $n = 4$ ) rosacea. IPL was effective at reducing symptoms with rosacea classified as absent in five women and mild in five at the final 3-month visit. GAIS scores also revealed improvements on both sides of the face, but the skincare treated side showed continuous improvement over 3 months with all patients remaining at least “Improved”, whereas there appeared to be a waning effect after 1 month with IPL alone. On Day 1 after IPL, all women reported less redness, improved hydration, and improved skin appearance on the right side of the face. Patient satisfaction was consistently rated higher on the right side of the face.

**Conclusion:** Application of a phyto-corrective mask, gel, and resveratrol antioxidant serum may complement IPL treatment for rosacea by enhancing treatment outcomes and reducing procedure-related symptoms.

## KEYWORDS

intense pulsed light, redness, rosacea, skin care, telangiectasia

## 1 | INTRODUCTION

Rosacea is a chronic inflammatory condition of the facial skin that primarily affects the forehead, nose, chin, and cheeks.<sup>1</sup> It is characterized by flare-ups and remissions and usually begins after the age of 30, with most cases occurring in those aged 45–60 years.<sup>2</sup> It can affect all populations, but is more commonly diagnosed in those with Fitzpatrick skin types I–II.<sup>3</sup> A systematic review of population-based and dermatological outpatient studies has estimated a global prevalence of 5.5% (approximately 415 million individuals).<sup>2</sup> In the US, the National Rosacea Society (NRS) estimates that around 16 million people are affected.<sup>4</sup> However, despite being a relatively common skin condition, only around 18% of Americans with rosacea are estimated to be receiving medical treatment.<sup>5</sup>

Phenotypes of rosacea range in severity and can be associated with significant facial symptoms and substantial psychological burden for the patient.<sup>6,7</sup> Papules and pustules are regarded as the most severe phenotype, but the prevalence of facial erythema is very high across all patients with rosacea.<sup>8</sup> Patients describe persistent facial redness as one of the most disruptive rosacea manifestations.<sup>9</sup> An NRS survey of over 700 rosacea patients, reported the condition has wide-ranging negative effects on health-related quality of life including lowered self-confidence and self-esteem, causing many to avoid public contact or cancel social engagements.<sup>9</sup>

Achieving optimal patient outcomes requires treatments to address facial erythema in addition to the papules and pustules.<sup>8</sup> Many of those with milder rosacea may not even realize they have a condition that can be treated, and instead use over-the-counter skin care products or cover their redness with makeup. In addition to identification and avoidance of patient-specific triggers, self-care advice, and general skin care measures, there are active treatment options available for addressing rosacea features. These include topical, oral, and physical modalities such as lasers and intense pulsed light (IPL). Expert consensus indicates that multiple rosacea symptoms are best managed using a combination of treatment modalities.<sup>10,11</sup>

Light devices such as IPL are well-established ways to effectively destroy telangiectasia, decrease inflammation, and to reduce erythema. IPL is light filtered to specific wavelengths, selected for their absorption by specific target tissues. To treat rosacea, dermatologists target oxyhemoglobin, a component in the walls of telangiectatic vessels. The telangiectasias selectively absorb the light, and the heat causes thrombosis, which closes the vessels. Treatment with IPL is also associated with other beneficial effects. It may boost the upregulation of anti-inflammatory cytokines and downregulation of proinflammatory cytokines.<sup>12,13</sup> IPL may also improve collagen synthesis and increase cellular metabolism by affecting the electron transport chain of mitochondria.<sup>14,15</sup>

However, while IPL is beneficial in breaking the cycle of inflammation involved in the symptoms of rosacea, it can be associated with significant downtime. The aim of this exploratory study was to determine whether the application of a phyto-corrective mask, gel, and a resveratrol antioxidant serum after IPL treatment for rosacea can improve outcomes and reduce procedure-related adverse effects.

## 2 | METHODS

This prospective, open-label, split-face, 3-month study enrolled 10 subjects presenting to a private aesthetic surgery practice with moderate-to-severe facial rosacea including persistent erythema and telangiectasia. Eligible subjects were men or women aged 18–80 years. Exclusion criteria for the study included: uncontrolled systemic disease; known allergy or sensitivity to study treatments or their components; active inflammatory or infectious process in the area to be treated (e.g., cysts, rashes, herpes simplex, herpes zoster, or precancerous lesions), or any other active or serious skin disease of the face; history of trauma or scarring associated with the area of the face being treated; facial hair that would interfere with treatment and evaluation; and a history of keloid scarring or a tendency to develop hypertrophic scarring. Female patients of child-bearing age were required to use a reliable method of contraception for the duration of the study. All patients in the study stopped using all other skincare products during the study. If a patient was receiving any oral or topical agents for rosacea, these were discontinued on entering a 2-week washout period and for the duration of this study.

All participants were required to show willingness and ability to comply with protocol requirements including ability to follow study instructions, return for follow-up visits, and abstain from any other procedures in the treated area throughout the study. All subjects provided signed informed consent to the procedure and to the subsequent use and release of health and research study information (including photographs) for scientific purposes. This study adhered to the tenets of the Declaration of Helsinki as amended in 2008 and was compliant with the Health Insurance Portability and Accountability Act (HIPAA), which ensures protection of individually identifiable health information, unless consented by the patient (Institutional Review Board No. Pro 00049130).

On Day 1, all subjects underwent IPL treatment of their rosacea on both sides of the face using a Spectrum laser/IPL system (Rohrer Aesthetics, LLC). One treatment was performed, 540nm, pulse duration 15ms, pulse train 10, 30J/cm<sup>2</sup>. No numbing medication was used to pre-treat the skin. Immediately following the IPL, subjects had a phyto-corrective mask applied on the right side of the face only for 15 minutes (Phyto Corrective Masque, SkinCeuticals). In addition,

TABLE 1 Rosacea clinical scorecard

Primary features				
Flushing (transient erythema)	Absent	Mild	Moderate	Severe
Nontransient erythema	Absent	Mild	Moderate	Severe
Papules and pustules	Absent	Mild	Moderate	Severe
Telangiectasia	Absent	Mild	Moderate	Severe
Secondary features				
Burning or stinging	Absent	Mild	Moderate	Severe
Plaques	Absent	Mild	Moderate	Severe
Dry appearance	Absent	Mild	Moderate	Severe
Edema	Absent	Mild	Moderate	Severe
If present:	Acute	Chronic		
If chronic:	Pitting	Non-pitting		
Ocular manifestations	Absent	Mild	Moderate	Severe
Peripheral location	Absent	Present		
If present:	List location(s)			
Phymatous changes	Absent	Mild	Moderate	Severe
Global assessment				
Physician ratings by subtype				
Subtype 1: Erythematotelangiectatic	Absent	Mild	Moderate	Severe
Subtype 2: Papulopustular	Absent	Mild	Moderate	Severe
Subtype 3: Phymatous	Absent	Mild	Moderate	Severe
Subtype 4: Ocular	Absent	Mild	Moderate	Severe
Patient's global assessment	Absent	Mild	Moderate	Severe

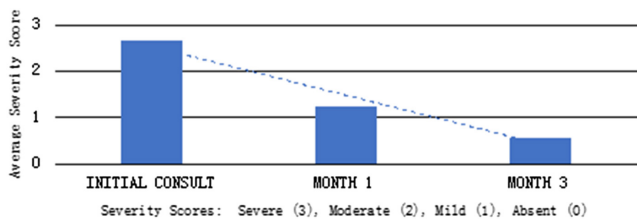


FIGURE 1 Rosacea symptom severity score based on primary physician assessment immediately after treatment and at 1 and 3 months

all subjects also applied the following treatment to the right side of the face only: phyto-corrective gel twice daily (Phyto Corrective gel, SkinCeuticals); resveratrol antioxidant treatment (Resveratrol B E, SkinCeuticals) at night-time; and the phyto-corrective mask once per week. Subjects treated both sides of the face with sunscreen (Sheer Physical UV Defense SPF 50, SkinCeuticals).

All individuals attended three follow-up visits; the first was 1 day after IPL treatment, the second was 1 month after treatment, and the third visit was 3 months after IPL treatment. At each visit, high-resolution photographs were taken. Subjects were also assessed live by the treating physician at each visit.

At each visit, the treating physician assessed the patient and completed a Rosacea Clinical Score Card, to provide information on signs and symptoms and the severity of the condition on the two sides of the face (Table 1). Subjective assessment of patients

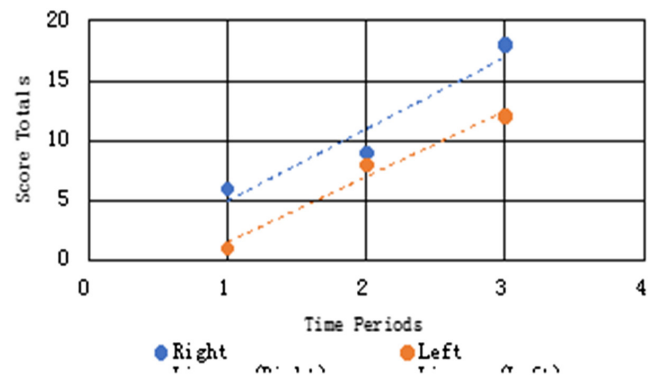


FIGURE 2 Total physician GAIS scores over time

was performed by three independent evaluators using the 5-point Global Aesthetic Improvement Scale (GAIS). This was achieved by comparing photographs of the left and right side of the patient's face before treatment and at each post-treatment visit and asking the question: "How would you describe the results?" The available choices were as follows: (-1) worse (the appearance is worse than at baseline), (0) no change (the appearance is basically the same as at baseline), (1) improved (the appearance is better than at baseline), (2) much improved (the appearance is markedly better than at baseline), and (3) very much improved (excellent cosmetic result). All subjects rated skin redness, hydration, and overall improvement on Day 1 after treatment. In addition, a patient satisfaction questionnaire was

completed at the 1- and 3-month visits with responses ranging from (1) Strongly disagree to (4) Strongly agree.

### 3 | RESULTS

The study enrolled 10 women, aged 44–72 years old, all of whom attended all study visits. At the initial visit, the rosacea was classed as severe in four women and moderate in six women (mean Rosacea symptom severity score 2.7) (Figure 1). At the final 3-month visit,

rosacea symptoms were classified as absent in five women and mild in five (mean score 0.6).

Adding the mean physician GAIS scores for all 10 patients and plotting over time revealed improvements on both sides of the face following IPL. Outcomes on the right side, which was treated with a combination of IPL and skincare treatments, showed continuous improvement over the 3 months of the study, and were rated higher by physicians at each visit compared with the side treated with IPL alone (Figure 2).

Analysis of the frequency of GAIS scores revealed that 40% of patients experienced immediate improvement on the right-side of

TABLE 2 Physician GAIS score for the right and left sides of the face at each visit

Right side of face (IPL + skincare treatment)			Left side of face (IPL alone)		
Day 1	Absolute frequency	Relative frequency	Day 1	Absolute frequency	Relative frequency
Very much improved	1	10%	Very much improved	0	0%
Much improved	0	0%	Much improved	3	30%
Improved	3	30%	Improved	0	0%
No change	6	60%	No change	5	50%
Worse	0	0%	Worse	2	20%
Month 1	Absolute frequency	Relative frequency	Month 1	Absolute frequency	Relative frequency
Very much improved	1	10%	Very much improved	2	20%
Much improved	1	10%	Much improved	4	40%
Improved	4	40%	Improved	0	0%
No change	4	40%	No change	4	40%
Worse	0	0%	Worse	0	20%
Month 3	Absolute frequency	Relative frequency	Month 3	Absolute frequency	Relative frequency
Very much improved	3	30%	Very much improved	2	20%
Much improved	2	20%	Much improved	6	60%
Improved	5	50%	Improved	1	10%
No change	0	0%	No change	1	10%
Worse	0	0%	Worse	0	0%

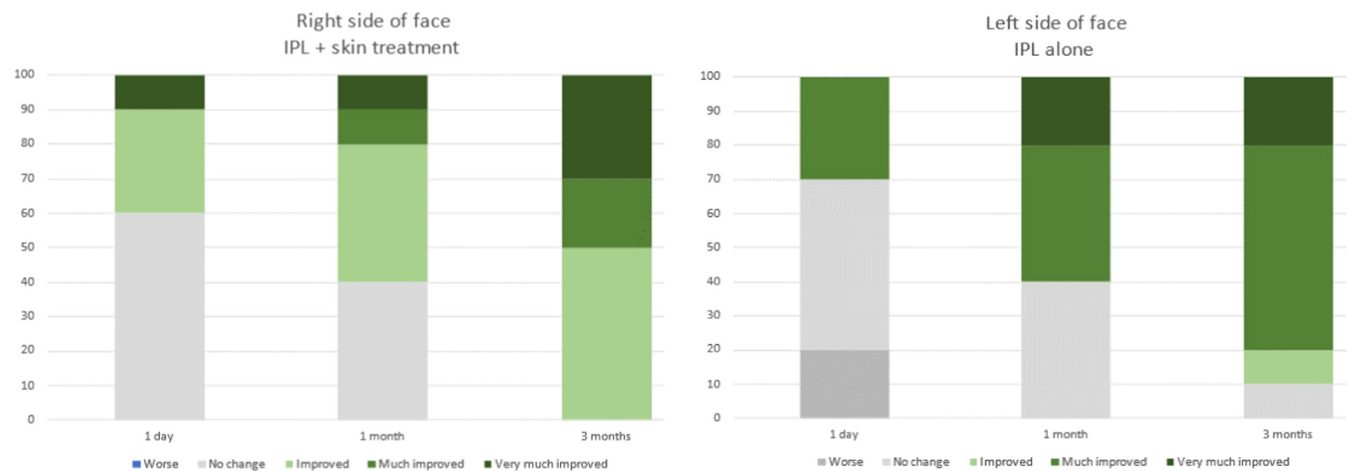
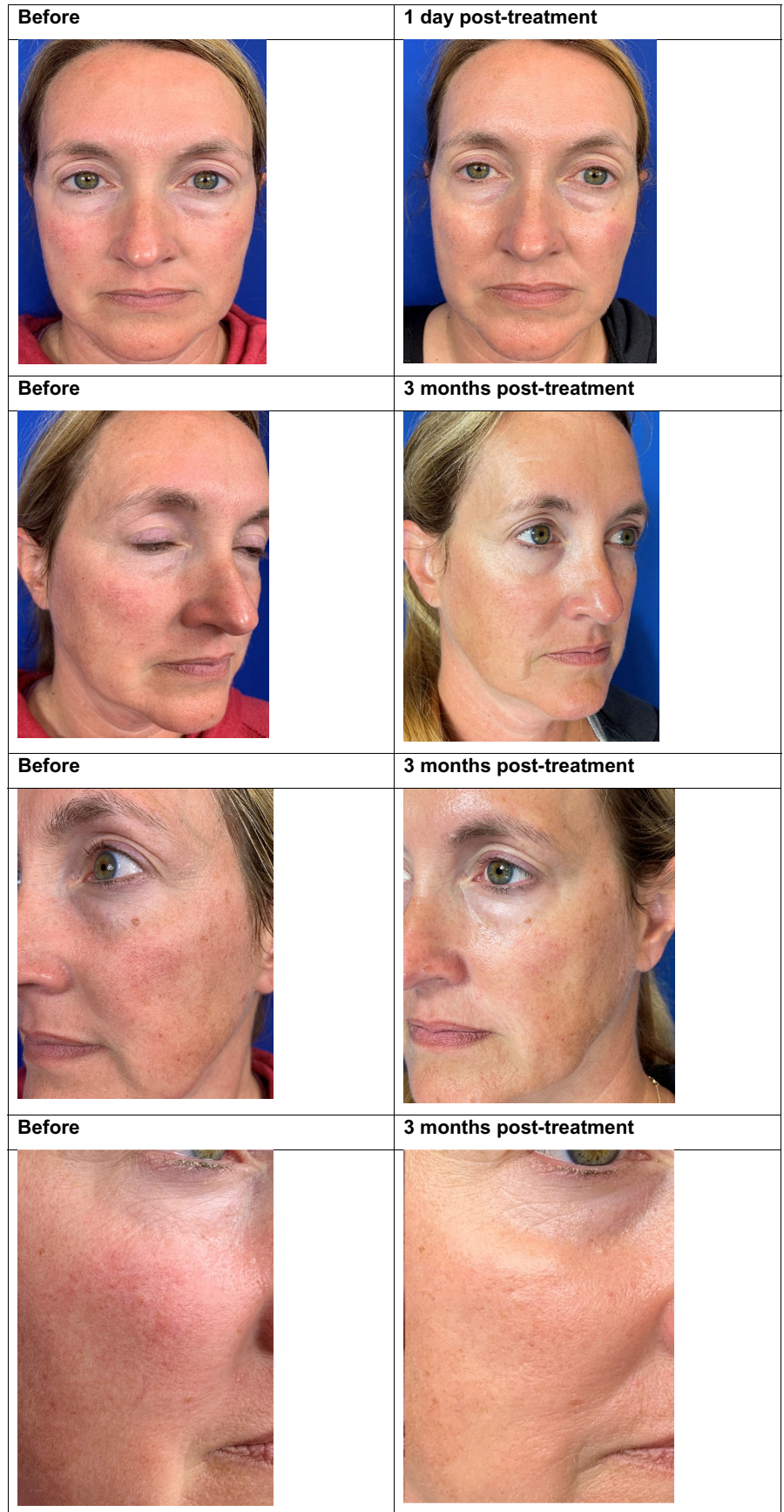
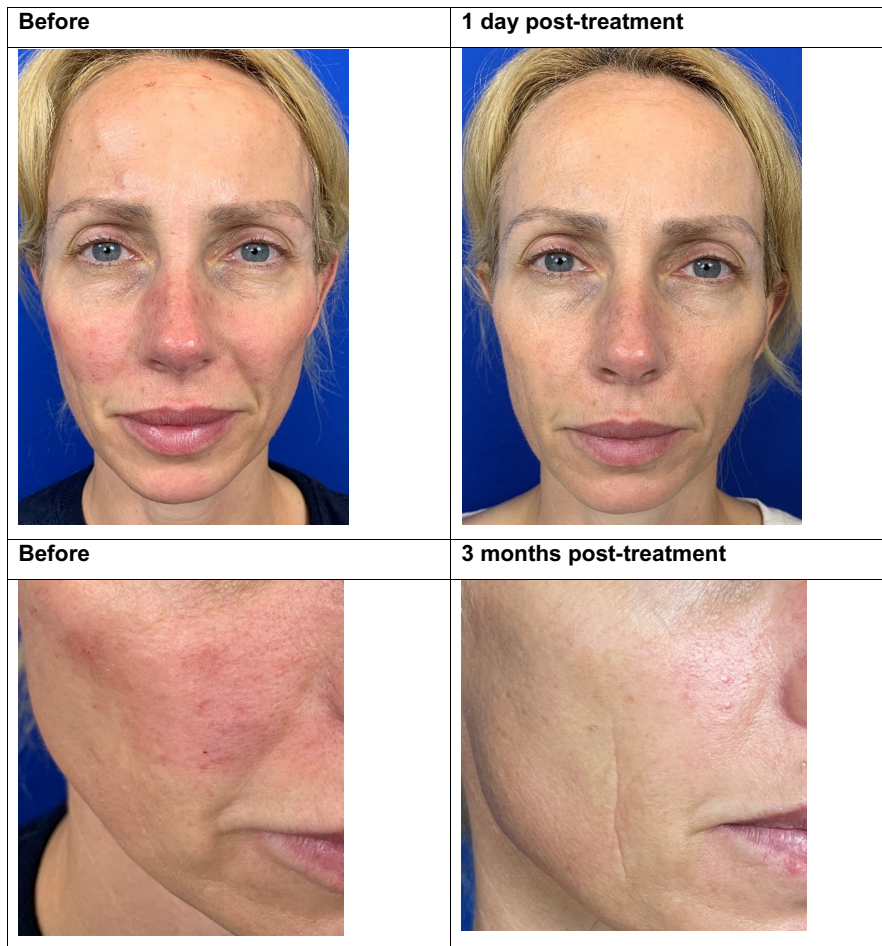

FIGURE 3 Evaluating physicians' GAIS scores at Day 1, 1- and 3-months follow-up showing percentage of subjects at each score

**FIGURE 4** Patient before and after treatment with IPL plus skincare regimen (right side) versus IPL alone (left side)







**FIGURE 5** Patient before and after treatment with IPL plus skincare regimen (right side) versus IPL alone (left side)

the face compared with 30% on the left (Table 2, Figure 3). On the right-side of the face, all patients remained at least “Improved” at the 3-month visit. In contrast, GAIS scores suggested that improvements had a shorter duration on the left side (Table 2, Figure 3). Before and after images of the right and left sides of the face immediately after treatment and at 3 months are shown in Figures 4 and 5.

All patients rated skin quality in terms of redness and hydration on Day 1 after treatment and unanimously reported less redness, improved hydration as well as an overall improvement in skin appearance on the skincare-treated side of the face (Figure 6).

For all six questions of the patient satisfaction questionnaire, patients rated the right (skincare-treated) side of the face much higher than the left (Table 3). Ratings for the right side of the face ranged from 3.5 to 4.0 (Somewhat agree to strongly agree) and for the left side of the face from 2.3 to 3.1 (Somewhat disagree to somewhat agree).

#### 4 | DISCUSSION

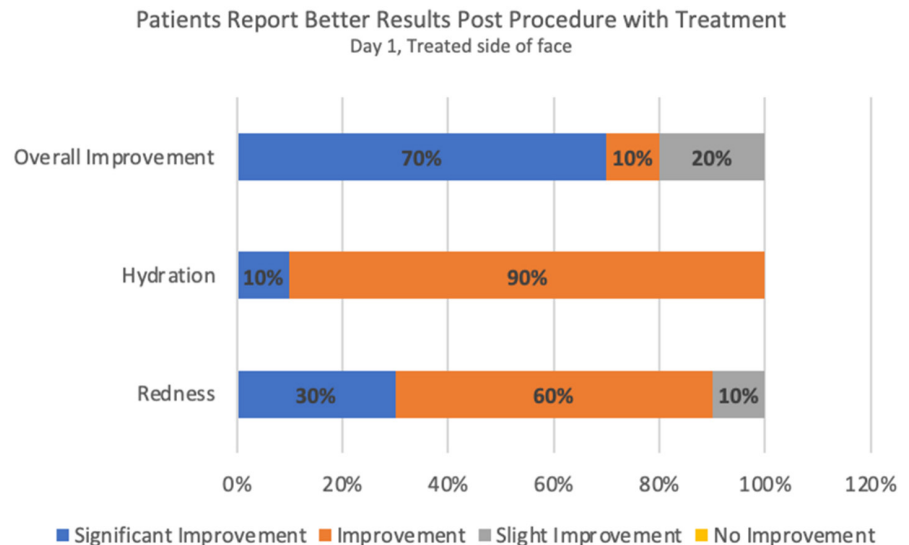
This proof-of-concept study has shown that when IPL treatment of rosacea is combined with effective skincare treatments, improved, and potentially longer-lasting outcomes are observed. Physician GAIS scores indicated that on the right (skincare-treated) side of

the face, patients experienced continuous improvements over the 3 months with positive results improving or compounding over time. In contrast, while improvements were also observed on the left (IPL alone) side of the face, they were not as pronounced.

Appropriate skincare treatments, particularly those with intrinsic anti-inflammatory and antioxidant properties, are recognized as an important component of a rosacea treatment plan.<sup>10</sup> These include cosmeceutical options with natural ingredients capable of calming the inflammatory manifestations of rosacea and hydrating the skin. In topical formulations, these treatments have demonstrated significant improvements in redness, flushing, skin tone, and overall rosacea severity when added to existing treatments.<sup>16</sup>

Rosacea is a chronic cutaneous inflammatory condition that consists of flare-ups and remissions. The avoidance of triggers, particularly ultraviolet light exposure, certain foods and beverages, is critical for long-term improvement and disease control.<sup>17</sup> Spicy foods, hot beverages, and alcohol are frequently reported to worsen rosacea symptoms and dietary modification to avoid these items is associated with a reduction in flare-ups.<sup>17,18</sup> Sun protection and awareness of dietary triggers should therefore be an essential component of patient education when prescribing at-home skin care and lifestyle adjustments. An SPF 50 UV defense formed part of the treatment regimen for both sides of the face in the current study. The goals of rosacea treatment are to improve patient quality of life

**FIGURE 6** Patient-rated skin improvement on skincare-treated side of face 1 day after treatment



**TABLE 3** Patient satisfaction questionnaire results at 1 month and 3 months

Question	Right side of the face (IPL + skincare treatment)		Left side of the face (IPL alone)	
	1 month	3 months	1 month	3 months
Were you pleased with results	3.7	3.9	2.7	2.9
Were you surprised by how great the results are	3.7	3.8	2.6	2.5
Result is fantastic	3.5	3.5	2.5	2.3
Best treatment for rosacea	4.0	3.9	2.4	2.5
Would pursue more treatments	3.8	3.8	3.0	3.1
Would recommend treatment	3.9	3.9	2.4	3.0

by managing acute flare-ups with rapid-acting treatments and maintaining the results with lifestyle modification and pharmacological and/or cosmeceutical products.<sup>10</sup> Light-based therapies such as IPL are particularly beneficial for treating the vascular manifestations of rosacea such as erythema and telangiectasia, which may not improve with other therapies.<sup>19</sup> However, while these treatments can help break the cycle of inflammation for many rosacea patients, they can themselves be associated with significant and meaningful downtime. Patients often experience excessive swelling for at least a week causing them to take time off work and avoid social interactions. Many patients cannot tolerate the downtime following an IPL procedure.

In the current study, improvements on the right side of the face were noted from Day 1 of treatment in 40% of patients, with the remaining 60% having no change in their appearance. In contrast, the side of the face treated with IPL alone was rated as worse on Day 1 in 20% of patients with no change in 50% of patients (Figure 2). This suggests that aside from improving the epidermal barrier, the inclusion of the phyto-corrective skincare regimen was able to immediately reduce some of the unwanted IPL side-effects such as redness and swelling and potentially reduce post-procedure downtime.

Previous studies in patients with rosacea and those with facial photodamage have demonstrated that a topical skin care regimen in combination with IPL results in a greater improvement in overall

facial redness than IPL alone.<sup>20,21</sup> When the epidermal barrier is disrupted as in rosacea, there is an increase in trans-epidermal water loss with a subsequent reduction in epidermal hydration levels, triggering inflammation.<sup>22</sup> Appropriate skin care formulations that increase hydration levels may reduce the damage to the stratum corneum, thereby maintaining the epidermal barrier function and reducing skin irritation.

The skincare products used in this study contained a variety of ingredients including hyaluronic acid, a biologic humectant, which hydrates the skin, and is useful as a topical moisturizing ingredient<sup>23</sup>; cucumber extracts which are anti-inflammatory and soothe irritation as well as reduce swelling<sup>24</sup>; thyme extracts which are antibacterial<sup>25</sup>; and the polyphenol, resveratrol, which promotes skin healing.<sup>26,27</sup> It has been shown that topical phenolic antioxidant application can augment the effects of IPL to further reduce the incidence of erythema and procedure-associated adverse effects.<sup>28,29</sup> Similar improvements have been observed with the use of a five-product system incorporating anti-inflammatory and anti-oxidant ingredients.<sup>30</sup>

On the treated side of the face, all patients reported improvements in skin redness, hydration, and overall appearance on Day 1 after treatment, with 70% reporting a significant improvement in overall appearance. These findings were also reflected in the patient satisfaction questionnaire results at both 1 and 3 months, with patients consistently giving higher ratings to the right side of the face.

Patient expectations for minimal to no downtime associated with cosmetic procedures, such as IPL, have become an increasingly important issue. The results of the current study suggest that the topical skin care regimen used was able to reduce procedure-related symptoms and possibly enhance therapeutic efficacy. The current study, while exploratory, is important as many patients are left with erythema despite current rosacea treatments and may be hesitant to undergo IPL because of the potential downtime involved. Any treatment that can improve the ability of patients to return to their daily lives and make them less self-conscious will improve patient quality of life and optimize outcomes. From the physician's perspective, improved results will lead to higher patient satisfaction and increased patient retention. Further studies are warranted, to confirm the observed findings in a larger number of patients.

## 5 | CONCLUSION

The results of this study show that a skincare regimen comprising a phyto-corrective mask, gel, and resveratrol antioxidant serum may complement IPL-based treatments for rosacea, enhance treatment outcomes, and reduce post-procedure symptoms.

### AUTHOR CONTRIBUTIONS

Sheila C. Barbarino was involved in conception, writing, reviewing, and revising the manuscript. Vivian W. Bucay, Joel L. Cohen, and Michael H. Gold were involved in reviewing and revising the manuscript.

### CONFLICT OF INTEREST

None.

### DISCLAIMER

We confirm that the manuscript has been read and approved by all the authors, that the requirements for authorship have been met, and that each author believes that the manuscript represents honest work.

### DATA AVAILABILITY STATEMENT

The data that support the findings of this study are available from the corresponding author on reasonable request.

### ETHICS STATEMENTS

This study adhered to the tenets of the Declaration of Helsinki as amended in 2008 and was compliant with the Health Insurance Portability and Accountability Act (HIPAA), which ensures protection of individually identifiable health information, unless consented by the patient (Institutional Review Board No. Pro 00049130).

### ORCID

Sheila C. Barbarino  <https://orcid.org/0000-0002-8367-8663>  
Michael H. Gold  <https://orcid.org/0000-0002-5183-5433>

## REFERENCES

1. Reinholz M, Ruzicka T, Steinhoff M, et al. Pathogenesis and clinical presentation of rosacea as a key for a symptom-oriented therapy. *J Dtsch Dermatol Ges*. 2016;14(Suppl 6):4-15.
2. Gether L, Overgaard LK, Egeberg A, Thyssen JP. Incidence and prevalence of rosacea: a systematic review and meta-analysis. *Br J Dermatol*. 2018 Aug;179(2):282-289.
3. Alexis AF, Callender VD, Baldwin HE, Desai SR, Rendon MI, Taylor SC. Global epidemiology and clinical spectrum of rosacea, high-lighting skin of color: review and clinical practice experience. *J Am Acad Dermatol*. 2019;80(6):1722-1729.e7.
4. Drake L. Rosacea now estimated to affect at least 16 million American. Rosacea.org. <https://www.rosacea.org/rosacea-review/2010/winter/rosacea-now-estimated-to-affect-at-least-16-million-americans>. Accessed March 8, 2022.
5. Wehausen B, Hill DE, Feldman SR. Most people with psoriasis or rosacea are not being treated: a large population study. *Dermatol Online J*. 2016;22(7):3.
6. Dai R, Lin B, Zhang X, Lou Y, Xu S. Depression and anxiety in rosacea patients: a systematic review and meta-analysis. *Dermatol Ther (Heidelb)*. 2021;11:2089-2105. doi:10.1007/s13555-021-00613-w
7. Zeichner JA, Eichenfield LF, Feldman SR, Kasteler JS, Ferrusi IL. Quality of life in individuals with erythematotelangiectatic and papulopustular rosacea: findings from a web-based survey. *J Clin Aesthet Dermatol*. 2018;11:47-52.
8. Gallo RL, Baldwin HE, Stein GL. Update on facial erythema in rosacea. *J Drugs Dermatol*. 2021;20(8):861-864.
9. Baldwin HE, Harper J, Baradaran S, Patel V. Erythema of rosacea affects health-related quality of life: results of a survey conducted in collaboration with the National Rosacea Society. *Dermatol Ther (Heidelb)*. 2019;9(4):725-734.
10. Schaller M, Almeida LM, Bewley A, et al. Rosacea treatment update: recommendations from the global ROSacea COnsensus (ROSCO) panel. *Br J Dermatol*. 2017;176:465-471.
11. Tan J, Almeida LM, Bewley A, et al. Updating the diagnosis, classification, and assessment of rosacea: recommendations from the global ROSacea COnsensus (ROSCO) panel. *Br J Dermatol*. 2017;176(2):431-438.
12. Byun JY, Choi HY, Myung KB, Choi YW. Expression of IL-10, TGF-beta (1) and TNF-alpha in cultured keratinocytes (HaCaT cells) after IPL treatment or ALA-IPL photodynamic treatment. *Ann Dermatol*. 2009;21(1):12-17.
13. Lee SY, Park KH, Choi JW, et al. A prospective, randomized, placebo-controlled, double-blinded, and split-face clinical study on LED phototherapy for skin rejuvenation: clinical, profilometric, histologic, ultrastructural, and biochemical evaluations and comparison of three different treatment settings. *J Photochem Photobiol B*. 2007;88(1):51-67.
14. Karu T. Primary and secondary mechanisms of action of visible to near-IR radiation on cells. *J Photochem Photobiol B*. 1999;49(1):1-17.
15. Farivar S, Malekshahabi T, Shiari R. Biological effects of low level laser therapy. *J Lasers Med Sci*. 2014;5(2):58-62.
16. Baldwin H, Berson D, Vitale M, Yatskayer M, Chen N, Oresajo C. Clinical effects of a novel topical composition on persistent redness observed in patients who had been successfully treated with topical or oral therapy for papulopustular rosacea. *J Drugs Dermatol*. 2014;13:326-331.
17. Weiss E, Katta R. Diet and rosacea: the role of dietary change in the management of rosacea. *Dermatol Pract Concept*. 2017;7(4):31-37.
18. Drake L. Hot sauce, wine and tomatoes cause flare-ups, survey finds. Rosacea.org. [https://www.rosacea.org/rr/2005/fall/article\\_3.php](https://www.rosacea.org/rr/2005/fall/article_3.php). Accessed March 8, 2022.
19. Husein-ElAhmed H, Steinhoff M. Light-based therapies in the management of rosacea: a systematic review with meta-analysis. *Int J Dermatol*. 2022;61(2):216-225.



20. Deaver Peterson J, Katz TM. Open-label study assessing the efficacy and tolerability of topical skin care and sun protection alone and in combination with intense pulsed light therapy. *J Cosmet Dermatol*. 2019;18(6):1758-1764.
21. Jones IT, Guiha I, Fabi SG. Open-label study assessing the efficacy and tolerability of topical skincare and sun protection products following intense pulsed light treatment. *J Cosmet Dermatol*. 2018;17(3):441-447.
22. Addor FA. Skin barrier in rosacea. *An Bras Dermatol*. 2016;91(1):59-63.
23. Draelos ZD, Diaz I, Namkoong J, Wu J, Boyd T. Efficacy evaluation of a topical hyaluronic acid serum in facial photoaging. *Dermatol Ther (Heidelb)*. 2021;11(4):1385-1394.
24. Mukherjee PK, Nema NK, Maity N, Sarkar BK. Phytochemical and therapeutic potential of cucumber. *Fitoterapia*. 2013;84:227-236.
25. Ustuner O, Anlas C, Bakirel T, et al. In vitro evaluation of antioxidant, anti-inflammatory, antimicrobial and wound healing potential of thymus sipyleus boiss. Subsp *Rosulans* (Borbas) *Jalas. Molecules*. 2019;24(18):3353.
26. Kallis PJ, Price A, Dosal JR, Nichols AJ, Keri J. A biologically based approach to acne and rosacea. *J Drugs Dermatol*. 2018;17(6):611-617.
27. Hecker A, Schellnegger M, Hofmann E, et al. The impact of resveratrol on skin wound healing, scarring, and aging. *Int Wound J*. 2022;19(1):9-28.
28. Freedman BM. Topical antioxidant application augments the effects of intense pulsed light therapy. *J Cosmet Dermatol*. 2009 Dec;8(4):254-259.
29. Freedman BM. Topical polyphenolic antioxidants reduce the adverse effects of intense pulsed light therapy. *J Cosmet Laser Ther*. 2009b;11(3):142-145.
30. Narurkar VA, Beer KR, Cohen JL. An open-label trial examining the efficacy and safety of a pre- and postprocedure topical five-product system (Clinique medical optimizing regimen) specifically formulated to complement laser/light-based facial cosmetic procedures. *J Cosmet Laser Ther*. 2010;12(6):288-295.

**How to cite this article:** Barbarino SC, Bucay VW, Cohen JL, Gold MH. Integrative skincare trial of intense pulsed light followed by the phyto-corrective mask, phyto-corrective gel, and resveratrol BE for decreasing post-procedure downtime and improving procedure outcomes in patients with rosacea. *J Cosmet Dermatol*. 2022;00:1-9. doi: [10.1111/jocd.15189](https://doi.org/10.1111/jocd.15189)